



Sybrachydactyly

What is sybrachydactyly?

Sybrachydactyly is a condition of short fingers that may be webbed or conjoined. Some or all of the fingers may be underdeveloped or not developed at all. Sybrachydactyly is a congenital condition, which means your baby was born with it.

Usually, only 1 hand is affected, most commonly the left hand. The muscles, nerves, tendons, ligaments and bones of the hand are usually also affected.

How common is sybrachydactyly?

It is rare and affects about 1 out of every 32,000 babies. It affects boys and girls equally.

What causes sybrachydactyly?

Most cases happen for no known reason and without any other abnormalities. It is not thought to be inherited or run in families.

Sometimes, sybrachydactyly is part of a genetic syndrome called Poland syndrome. This causes an underdeveloped chest muscle on 1 side of the body.

How is sybrachydactyly diagnosed?

Sybrachydactyly is most often seen at birth when a doctor does a newborn exam. Sometimes it is seen on a prenatal ultrasound.

Your child will have X-rays to look more closely at the underlying structure of your baby's fingers and to decide on treatment.

Sybrachydactyly is often confused with a hand disorder called constriction ring syndrome. The main difference is that sybrachydactyly often involves malformation of underlying

structures of the hand (muscles, nerves, bones). Constriction ring syndrome happens when a band constricts a normally developed finger, toe or limb while a fetus is developing.

How is sybrachydactyly treated?

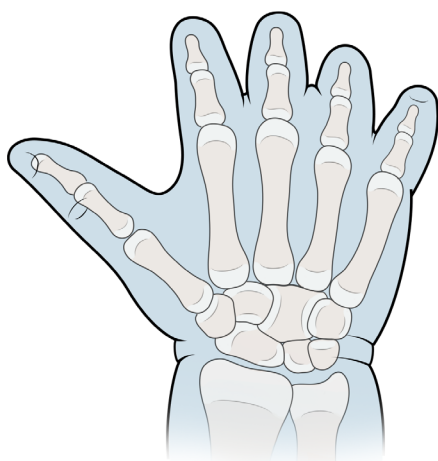
Treatment varies from child to child. Some children do not need surgery or only have minor skin and soft-tissue corrections. Other children may be candidates for various types of surgeries to add length to the affected fingers.

Surgery to separate fingers is usually done when a child is 1-2 years old. Sometimes, additional surgery is needed when children are older.

Your child will need follow-up visits to make sure they are healing and to test their hand movement. Your child may need to be seen for years to decide if they more surgery to improve their hand movement or how it looks.

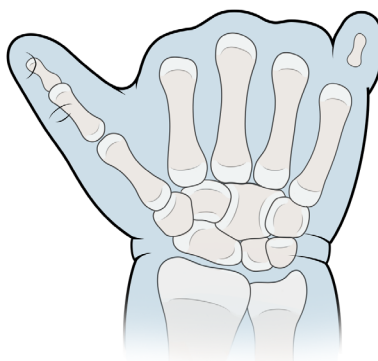
What are the types of sybrachydactyly?

Short finger



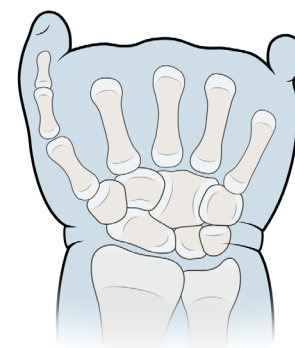
The thumb is basically normal, but the remaining fingers are short and stiff and may be webbed. This is the most common type.

Monodactylous/Bidactylous



There is only the thumb or the thumb and little finger.

Adactylous/Peromelic



All the fingers are missing; most children with this type have small skin stumps or nubbins in place of fingers.

